

## CHRONIC (50 YEARS) VENOUS ULCER HEALING BY ELECTROSTIMULATION

Also presented at: *American Venous Forum, San Diego 2007*

F. Zuccarelli<sup>1</sup>, J. Le Magrex<sup>1</sup>, M. Pujol<sup>2</sup>, J.Cywinski<sup>3</sup>

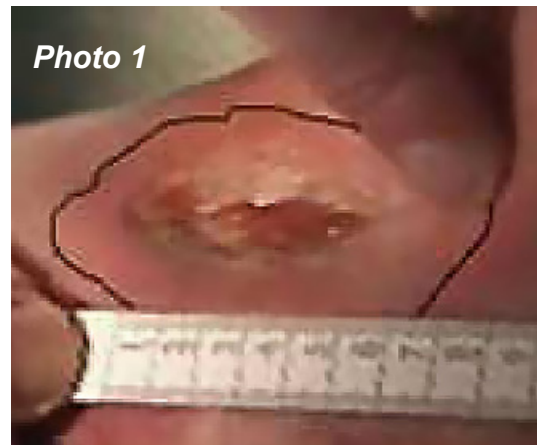1 : Phlebology Service, Hôpital Saint-Michel, 33 rue Olivier-de-Serres, F- 75015 Paris.

2 : INSEP, 11, avenue du Tremblay, F-75012 Paris.

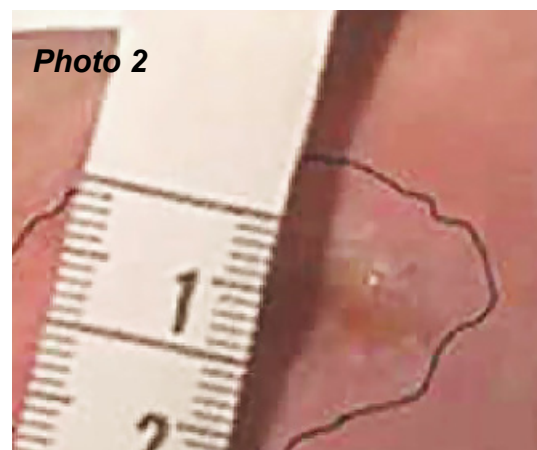
3 : Institute of Medical Technology, C.P.17, CH-1937 Orsières, Switzerland.

Patient M.G. born in 1935, in January 1953 was diagnosed with thrombosis of deep veins in the right leg. Bedridden for two months and treated with heparin and anti-vitamin K, developed thrombosis also in the left leg and multiple hematomas. Released from hospital in March 1953, readmitted in August 1953 with an ulcer of 8 cm in length, above right ankle. Treated with topical application of placenta and IV Novocaine + antibiotic. July 1954 after 1 year of in-hospital treatments was released for at-home care with non-healing bilateral ulcers. Readmitted to hospital at the end of 1954 received bilateral skin grafts. From 1957 till 2002, the ulcers alternatively reopened or partially healed. In May 2002 was admitted to Hospital St. Michel with post-thrombotic syndrome with bilateral nonhealed venous ulcers. Presented no problem with ambulation. The ulcers were located on interior sides of ankles with open cryptogenic aspect and atonic separating borders. Treated with multilayer contention + detergent the ulcer on the left leg closed, but on the right leg remained open in spite of antibiotic therapy and enzymatic cleaning of the ulcer opening. Since November 2004 M.G was treated at home with the Veinoplus stimulator for 20 min. daily. After 3 months the open right ulcer has diminished significantly (photo 1). After 6 months from the start of stimulation, the ulcer almost completely healed as shown on the Photo 2. Until May 2006 while continuing daily stimulations, no reoccurrence of active ulcers was observed. In May 2006 M.G. stopped the stimulation for personal reasons.

In June 2006, the examining phlebologist observed reactivation and reopening of the ulcer. After one month, while reestablishing daily stimulations (20 minutes) with VEINOPLUS®, the ulcer healed completely again. In conclusion, the results of healing venous ulcers are encouraging and are warranting to enter into controlled clinical studies on this subject.



*3 months after start of Veinoplus®*



*6 months after start of Veinoplus®*